

Sentinel Lymph Node Biopsy in Conjunctival Malignant Melanoma at the Lacrimal Caruncle : A Case Report

メタデータ	言語: English 出版者: OSAKA CITY MEDICAL ASSOCIATION 公開日: 2018-07-25 キーワード (Ja): キーワード (En): Conjunctival malignant melanoma, Lymphatic mapping, Sentinel lymph node biopsy 作成者: 元村, 尚嗣 , 坂本, 道治, 丸山, 陽子, 原田, 輝一, 石井, 正光 メールアドレス: 所属: Osaka City University, Osaka City University, Osaka City University, Osaka City University, Osaka City University
URL	https://ocu-omu.repo.nii.ac.jp/records/2020227

Sentinel Lymph Node Biopsy in Conjunctival Malignant Melanoma at the Lacrimal Caruncle: A Case Report

HISASHI MOTOMURA, MICHIHARU SAKAMOTO, YOKO MARUYAMA,
TERUICHI HARADA, and MASAMITSU ISHII

Citation	Osaka City Medical Journal.
Issue Date	2010-06
Type	Journal Article
Textversion	Publisher
Right	© Osaka City Medical Association. https://osakashi-igakukai.com/ .

Placed on: Osaka City University Repository

Sentinel Lymph Node Biopsy in Conjunctival Malignant Melanoma at the Lacrimal Caruncle: A Case Report

HISASHI MOTOMURA, MICHIHARU SAKAMOTO, YOKO MARUYAMA,
TERUICHI HARADA, and MASAMITSU ISHII

*Department of Plastic and Reconstructive Surgery, Osaka City University,
Graduate School of Medicine*

Abstract

Background

Conjunctival malignant melanoma (CMM) is so rare that there are no certain guidelines for its treatment. Factors influencing its prognosis include region of onset, tumor thickness, lymph node metastasis, and distant metastasis. Whether regional lymph node metastasis is present or not is one of the most powerful factors for predicting recurrence in and survival of patients with CMM.

Methods

A 72-year-old man with conjunctival malignant melanoma at the lacrimal caruncle was underwent sentinel lymph node (SLN) biopsy by preoperative lymphoscintigraphy and intraoperative vital blue mapping.

Results

A blue-dyed node could be identified in the superficial lobe of the parotid gland. A split half of the cropped SLN was immediately submitted to rapid pathological examination. After confirming no metastasis, it was decided not to perform lymph node dissection. The final diagnosis was pT₃N₀M₀. Neither recurrence nor distant metastasis has been observed for 7 years after the operation.

Conclusions

We were able to evaluate N (lymph node metastasis) in the TNM classification accurately. SLN may facilitate N classification and decisions regarding employment of appropriate lymph node dissection as well as combined therapy after operation.

Key Words: Conjunctival malignant melanoma; Lymphatic mapping; Sentinel lymph node biopsy

Received January 7, 2010; accepted April 13, 2010.

Correspondence to: Hisashi Motomura, MD.

Department of Plastic and Reconstructive Surgery, Osaka City University, Graduate School of Medicine
1-4-3 Asahimachi, Abeno-ku, Osaka 545-8585, Japan

Tel: +81-6-6645-3892; Fax: +81-6-6646-6059

E-mail: motomura@med.osaka-cu.ac.jp

Introduction

Conjunctival malignant melanoma (CMM) is very rare¹⁻³⁾. Its annual incidence in Japan is reported to be 0.059 patients in one million people⁴⁾. Factors influencing on prognosis include a region of onset, tumor thickness, lymph node metastasis, and distant metastasis^{1,2,5)}. Although a TNM classification for CMM has been proposed by the International Union Against Cancer (UICC)⁶⁾, stage-classified therapeutic principle like that for dermatogenic malignant melanoma (DMM) has not been established yet. We experienced a case of CMM at the lacrimal caruncle and performed sentinel lymph node (SLN) biopsy by preoperative lymphoscintigraphy and intraoperative vital blue mapping.

Case Report

A 72-year-old man has been aware of a black spot at the left lacrimal caruncle for 3 years. It gradually enlarged, and for 2 years had protruded externally even with the eyelids closed. It was left untreated due to lack of subjective symptoms. However, due to rapid enlargement of the tumor beginning 2 months previously, the patient consulted an ophthalmologist (Fig. 1). Histopathological examination yielded the diagnosis of CMM with a Breslow's tumor thickness of 3 mm. No metastases were observed on gallium scintigraphy and CT examination. The patient was referred to our department for surgical treatment.

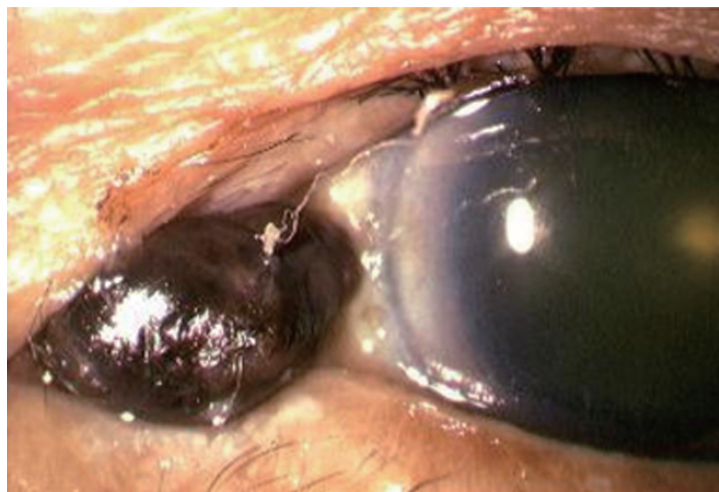


Figure 1. Malignant melanoma at the left lacrimal caruncle. It gradually enlarged and had protruded externally even when the eyelids were closed since two years previously.

Lymphatic mapping and SLN biopsy

The technique of lymphatic mapping and SLN biopsy of CMM has been reported previously⁷⁻¹¹⁾. Briefly, approximately 1 mCi of Technetium-99m-human serum albumin (Tc-99m-HSA) was intradermally injected around the lesion. SLN with high RI concentration could be identified as a hot spot with a gamma camera at 30 minutes and 2 hours after injection. Lymphoscintigraphy revealed that Tc-99m-HSA has accumulated in the anteroauricular region (Fig. 2).

The operation was performed under general anesthesia. Hand-held gamma counter was not available yet in our facility, so lymphatic mapping was initially conducted by a vital blue dye mapping technique (Fig. 3). Approximately 1 mL of 2.5% Patent Blue V was locally injected around the lesion, and then skin incision was performed 20 minutes after the local injection. Although no blue-dyed lymph nodes were found in the subcutaneous tissue in the

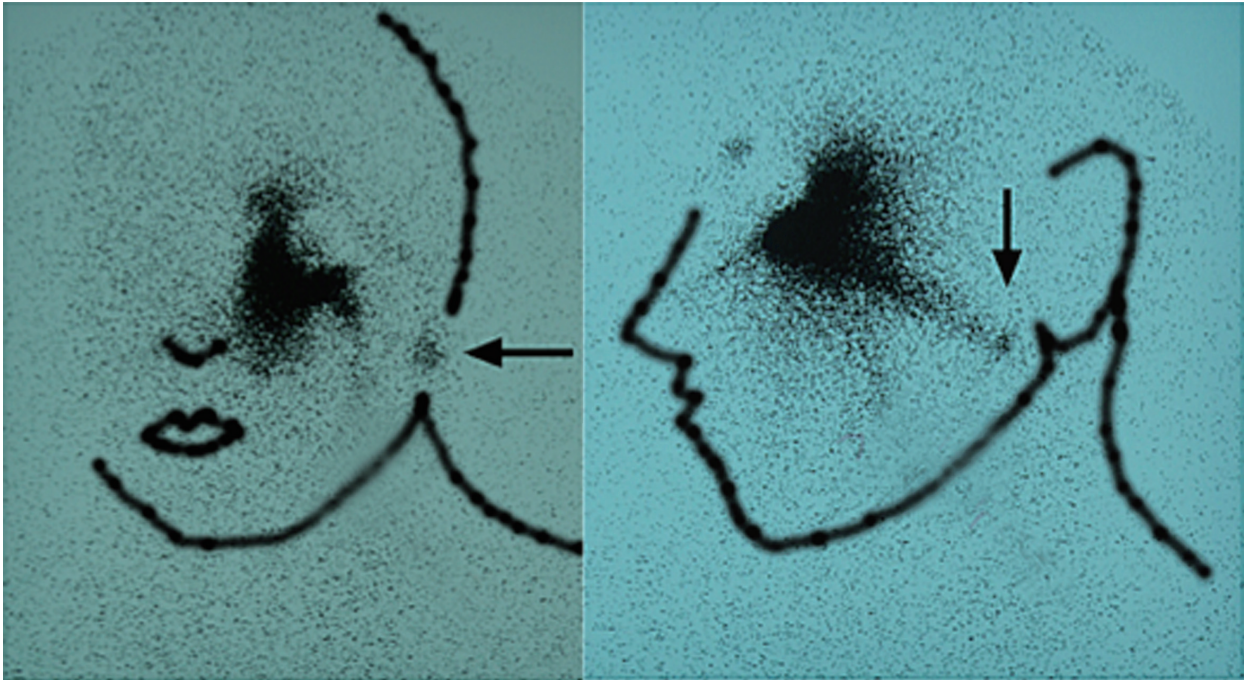


Figure 2. Sentinel lymph node on preoperative lymphoscintigraphy. Technetium-99m-human serum albumin accumulation was focally observed in the parotid regions (arrow).

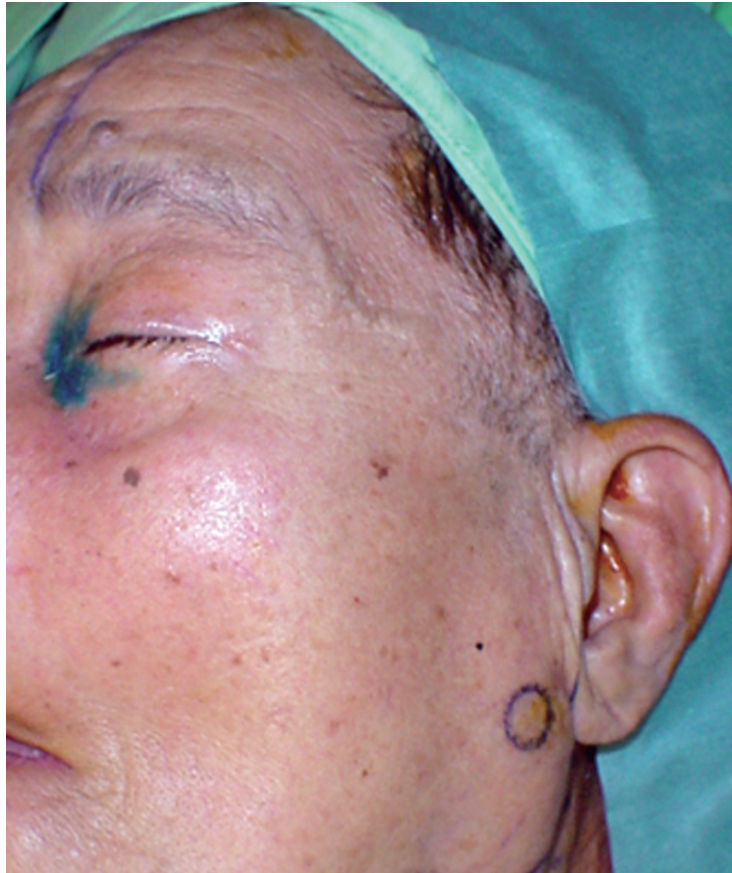

Figure 3. Approximately 1 mL of 2.5% Patent Blue V was locally injected around the lesion, and lymphatic mapping was conducted by a vital blue dye mapping technique. The region identified on preoperative lymphoscintigraphy was marked on the skin.

anteroauricular region, after resecting the superficial lobe of the parotid gland, a blue-dyed node could be identified in the superficial lobe of the parotid gland (Fig. 4). A split half of the cropped SLN was immediately submitted to rapid pathological examination. After confirming lack of metastasis, it was decided not to perform lymph node dissection. The lacrimal caruncle and the adjacent conjunctiva 4 mm out, including the cicatricial region, were resected, and cryotherapy was performed in the remaining region. The skin of the upper and lower eyelids was resected whole thickness to 1 cm out from the lesion. The medial canthal portion was reconstructed with a median forehead flap. The lacrimal duct was also reconstructed with the intraoral mucous

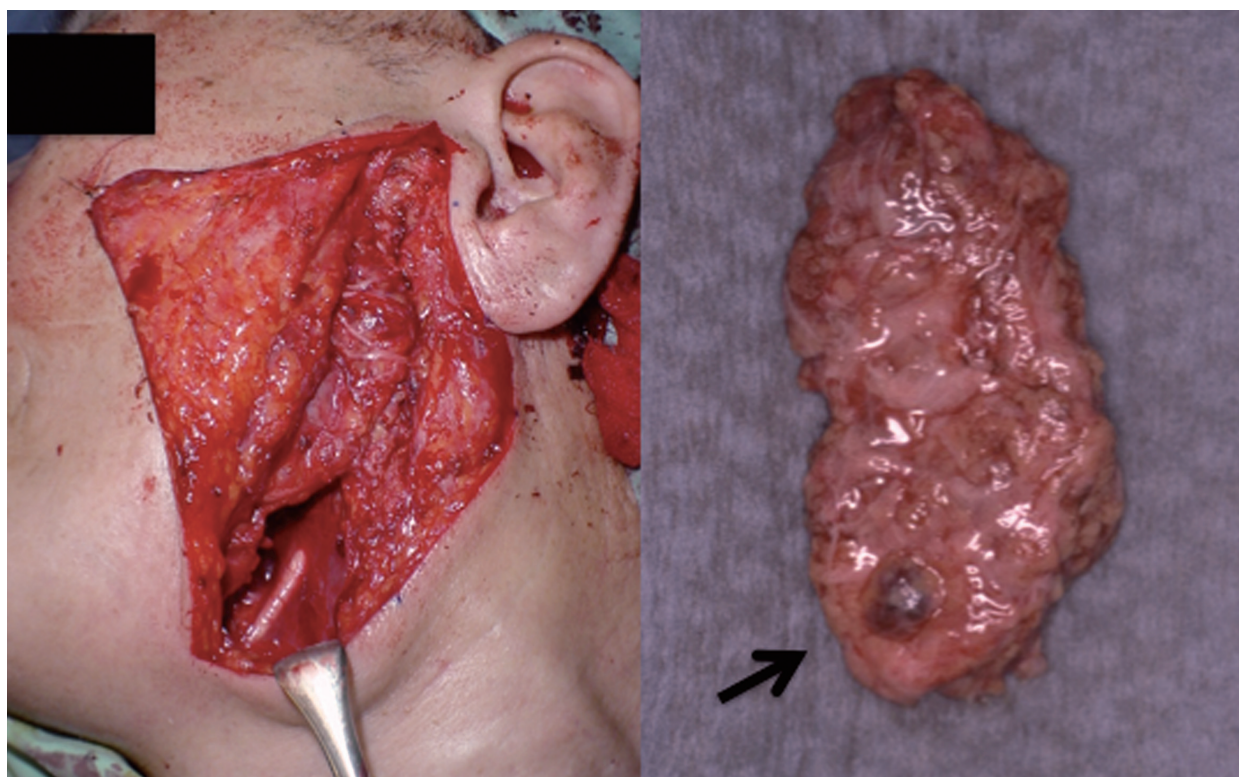


Figure 4. The superficial lobe of the parotid gland was resected. A blue-dyed lymph node can be identified on the deep side of the superficial lobe (arrow).

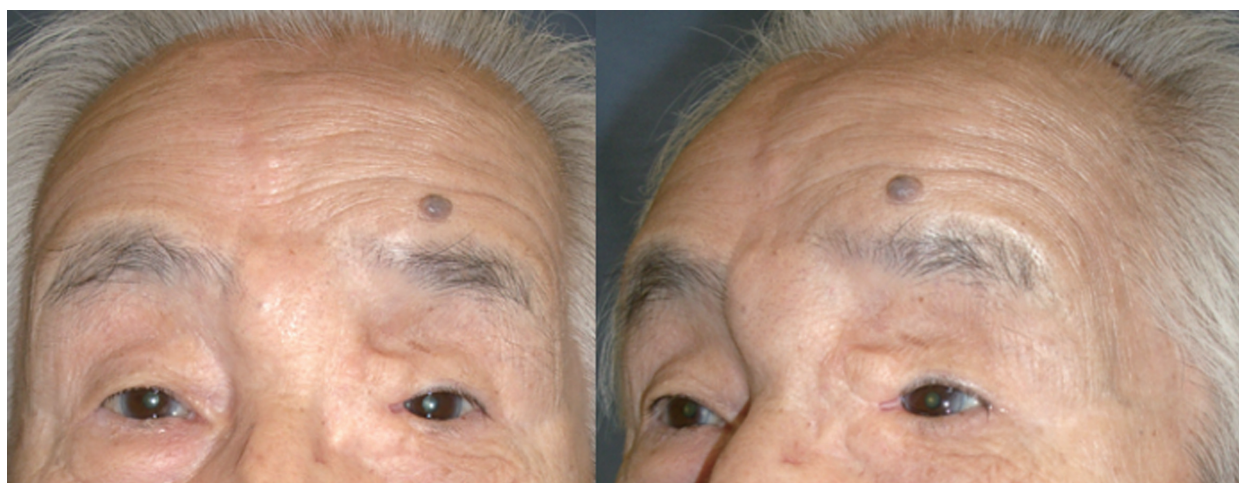

Figure 5. Neither recurrence nor metastasis has been observed for 7 years after the operation.

membrane. In the permanent specimen, no metastasis of the tumor was observed in the isolated SLN histologically. The final diagnosis was pT₃N₀M₀.

Neither recurrence nor distant metastasis has been observed for 7 years after the operation (Fig. 5).

Discussion

When tumor thickness is less than 1.5 mm, the prognosis of CMM, if treated by simple resection, is favorable. When tumor thickness exceeds 2 mm, however, careful planning of operation is required, since it is reported that prognoses are poor even treated with orbital exenteration¹²⁾. In our case, the conjunctiva was resected to 4 mm out from the tumor by no touch technique, and cryotherapy to the surrounding conjunctiva was performed, as mentioned in a report by Shields et al¹³⁾. Primary tumors extending beyond the bulbar conjunctiva of the lacrimal caruncle, fornix, and palpebral conjunctiva are classified as T₃, regardless of tumor depth, and this is one of the factors influencing on prognosis¹⁴⁾. This classification reflects the complicated lymph flow system in this area, since those regions are at connecting line of dermal fusion. Direct propagation of tumor cells is considered possible via direct infiltration from the conjunctiva, contact seeding by blinking, or minute injury due to rubbing. Therefore, care is required in handling not only the conjunctiva but also the surrounding skin and soft tissue. It is necessary to confirm lack of infiltration of tumor cells by rapid pathological examination in the skin sample resected with a safety margin of at least 1 cm around the lesion. In our case, the skin at the medial angle of the eyelid was resected to 1 cm away from the lesion whole thickness, and no tumor cells were found there.

Whether regional lymph node metastasis is present or not is one of the most significant factor for predicting recurrence and survival of patients with CMM. CMM grows expansively and metastasizes to the lymph nodes like DMM, and is liable to cause lymphogenous metastasis¹⁵⁾. In particular, primary tumors at the lacrimal caruncle, fornix and palpebral conjunctiva are near the surrounding skin. It is generally understood that lymph from medial orbital sites flows into the submandibular region while lymph from lateral orbital sites flows into the anteroauricular region, whereas lymph flow in the head and neck is too complex to predict. SLNs, the first lymph nodes into which lymph drains from the primary tumor site, have been shown to reflect the histological features of the remainder of the lymphatic basin in patients with melanoma¹⁶⁾. It has come to be considered that the state of the said lymph node metastasis accurately reflects the metastatic state of the whole pertaining lymph nodes. Therefore, lack of SLN metastasis suggests lack of lymph nodal metastases, whereby accurate evaluation of N is possible. On the other hand, no metastasis in this lymph node precludes requirement of elective lymph node dissection, and therapeutic lymph node dissection is required only in cases with metastasis. The above is the widely introduced concept for DMM, whereas this concept is not commonly accepted for CMM yet. But since when Esmaeli et al performed the SLN biopsy for a CMM⁷⁾, there are some reports of the SLN biopsy for CMM⁸⁻¹¹⁾. Lymphatic mapping with radiolymphoscintigraphy and vital dye injection are available for identification of SLNs¹⁷⁻²¹⁾. In our case, preoperative lymphoscintigraphy revealed Tc-99m-HSA accumulation in the anteroauricular. By vital dye injection, we could confirm the lymph node at the anteroauricular region, which was finally found in the superficial lobe of the parotid gland, as the proper SLN. Neither recurrence nor

distant metastasis has been observed for 7 years after the operation, so we evaluated our treatment plan to be correct. Hand-held gamma counter had not been available at that time, but more precise research may be warranted now.

Accurate identification of SLNs appears to enable accurate evaluation of N, finally facilitating decisions regarding employment of appropriate lymph node dissection as well as combined therapy after operation. Establishment of therapeutic guidelines on the basis of accurate staging may be possible with accumulation of cases.

References

1. Paridaens AD, Minassian DC, McCarthey AC, Hungerford JL. Prognostic factors in primary malignant melanoma of the conjunctiva: a clinicopathological study of 256 cases. *Br J Ophthalmol* 1994;78:252-259.
2. Seregard S. Conjunctival melanoma. *Surv Ophthalmol* 1998;42:321-350.
3. Shields CL, Shields JA, Gündüz K, Cater J, Mercado GV, Gross N, et al. Conjunctival melanoma: risk factors for recurrence, exenteration, metastasis, and death in 150 consecutive patients. *Arch Ophthalmol* 2000;118:1497-1507.
4. Kaneko A. Incidence of malignant melanoma of the eye in Japan. *Clinical Ophthalmology* 1979;33:941-947. (in Japanese)
5. Folberg R, McLean IW, Zimmerman LE. Malignant melanoma of the conjunctiva. *Hum Pathol* 1985;16:136-143.
6. Sobin LH, Wittekind Ch. TNM classification of malignant tumours. 6th ed. New York: Wiley-Liss; 2002. pp. 215-217.
7. Esmaeli B, Eicher S, Popp J, Delpassand E, Prieto VG, Gershenwald JE. Sentinel lymph node biopsy for conjunctival melanoma. *Ophthal Plast Reconstr Surg* 2001;17:436-442.
8. Amato M, Esmaeli B, Ahmadi MA, Tehrani MH, Gershenwald J, Ross M, et al. Feasibility of preoperative lymphoscintigraphy for identification of sentinel lymph nodes in patients with conjunctival and periocular skin malignancies. *Ophthal Plast Reconstr Surg* 2003;19:102-106.
9. Baroody M, Holds JB, Kokoska MS, Boyd J. Conjunctival melanoma metastasis diagnosed by sentinel lymph node biopsy. *Am J Ophthalmol* 2004;137:1147-1149.
10. Esmaeli B, Reifler D, Prieto VG, Amir Ahmadi M, Hidaji L, Delpassand E, et al. Conjunctival melanoma with a positive sentinel lymph node. *Arch Ophthalmol* 2003;121:1779-1783.
11. Tuomaala S, Kivelä T. Metastatic pattern and survival in disseminated conjunctival melanoma: implications for sentinel lymph node biopsy. *Ophthalmology* 2004;111:816-821.
12. Silvers DN, Jakobiec FA, Freeman TR. Melanoma of conjunctiva: a clinicopathologic study. In: Jakobiec FA, editor. *Ocular and adnexal tumors*. Birmingham: Aesculapius; 1978. pp. 583-599.
13. Shields JA, Shields CL, De Potter P. Surgical management of conjunctival tumors. The 1994 Lynn B. McMahan Lecture. *Arch Ophthalmol* 1997;115:808-815.
14. Anastassiou G, Heiligenhaus A, Bechrakis N, Bader E, Bornfeld N, Steuhl KP. Prognostic value of clinical and histopathological parameters in conjunctival melanomas: a retrospective study. *Br J Ophthalmol* 2002;86:163-167.
15. Spencer WH, Zimmerman LE. Conjunctiva. In: Spencer WH, editor. *Ophthalmic Pathology*. Philadelphia: WB Saunders; 1985. pp. 192-220.
16. Johnson TM, Yahanda AM, Chang AE, Fader DJ, Soudak VK. Advances in melanoma therapy. *J Am Acad Dermatol* 1998;38:731-741.
17. Kapteijn BA, Nieweg OE, Liem I, Mooi WJ, Balm AJ, Muller SH, et al. Localizing the sentinel node in cutaneous melanoma: gamma probe detection versus blue dye. *Ann Surg Oncol* 1997;4:156-160.
18. Motomura H, Nose K, Fujiwara M, Muraoka M. Lymphatic mapping and sentinel lymph node biopsy in patient with malignant melanoma. *Japanese Journal of Plastic Surgery* 2002;45:251-258. (in Japanese)
19. Pu LL, Cruse CW, Wells KE, Cantor A, Glass LF, Messina JL, et al. Lymphatic mapping and sentinel lymph node biopsy in patients with melanoma of the lower extremity. *Plast Reconstr Surg* 1999;104:964-969.
20. Wagner JD, Corbett L, Park HM, Davidson D, Coleman JJ, Havlik RJ, et al. Sentinel lymph node biopsy for melanoma: experience with 234 consecutive procedures. *Plast Reconstr Surg* 2000;105:1956-1966.
21. Motomura H, Ishii M. Lymphatic mapping and sentinel lymph node biopsy for malignant melanoma in Japanese. *Osaka City Med J* 2004;50:29-37.